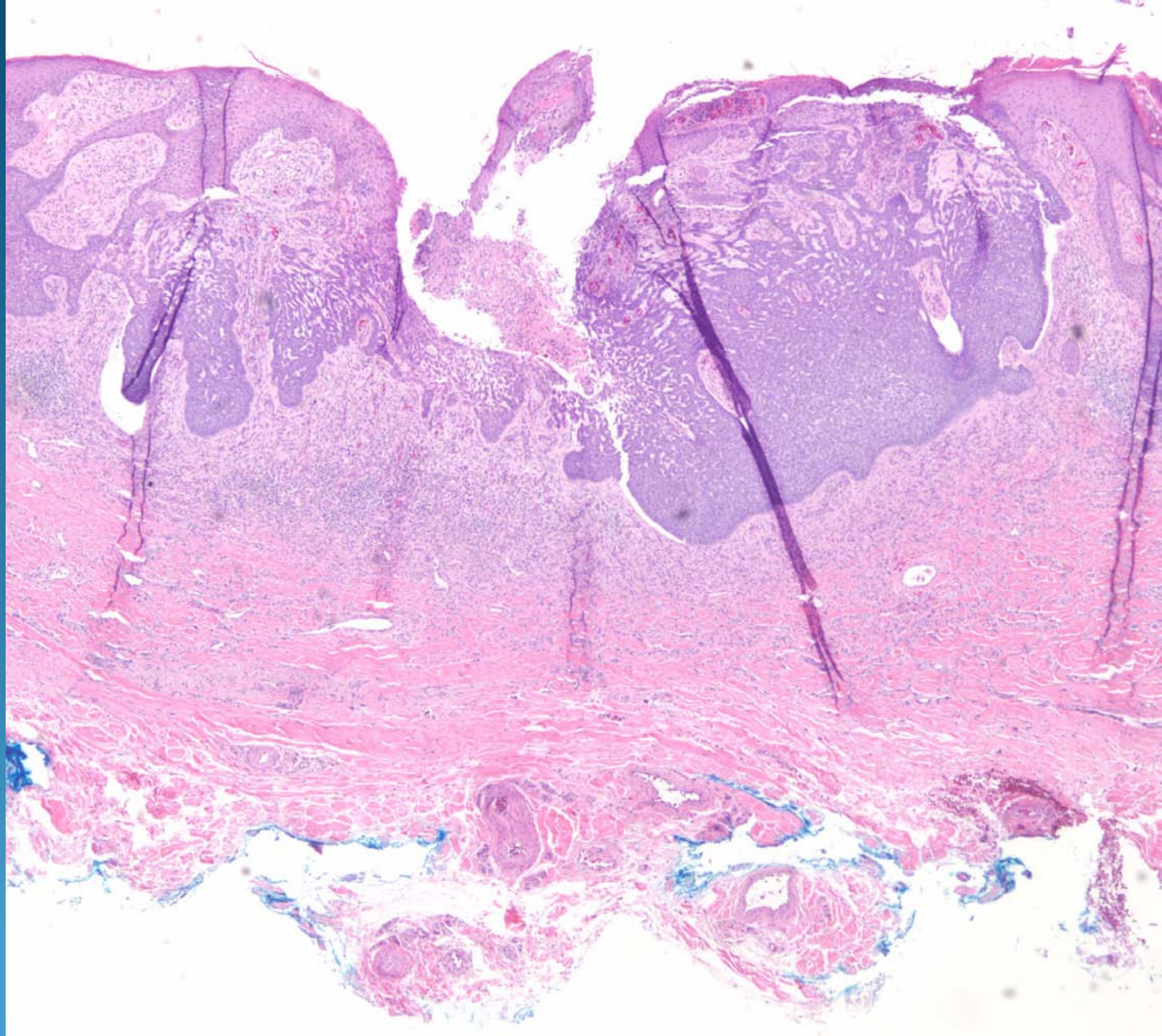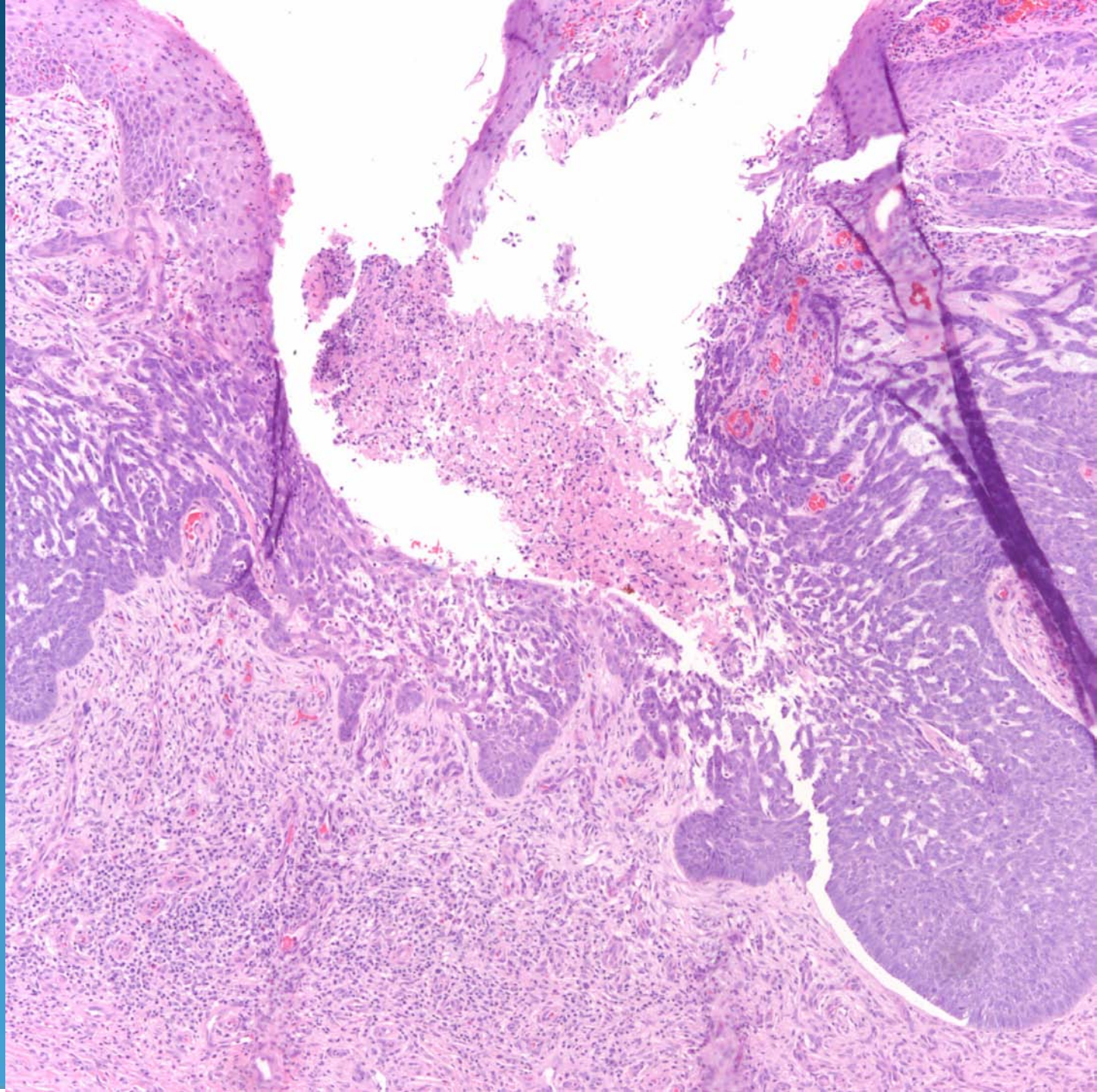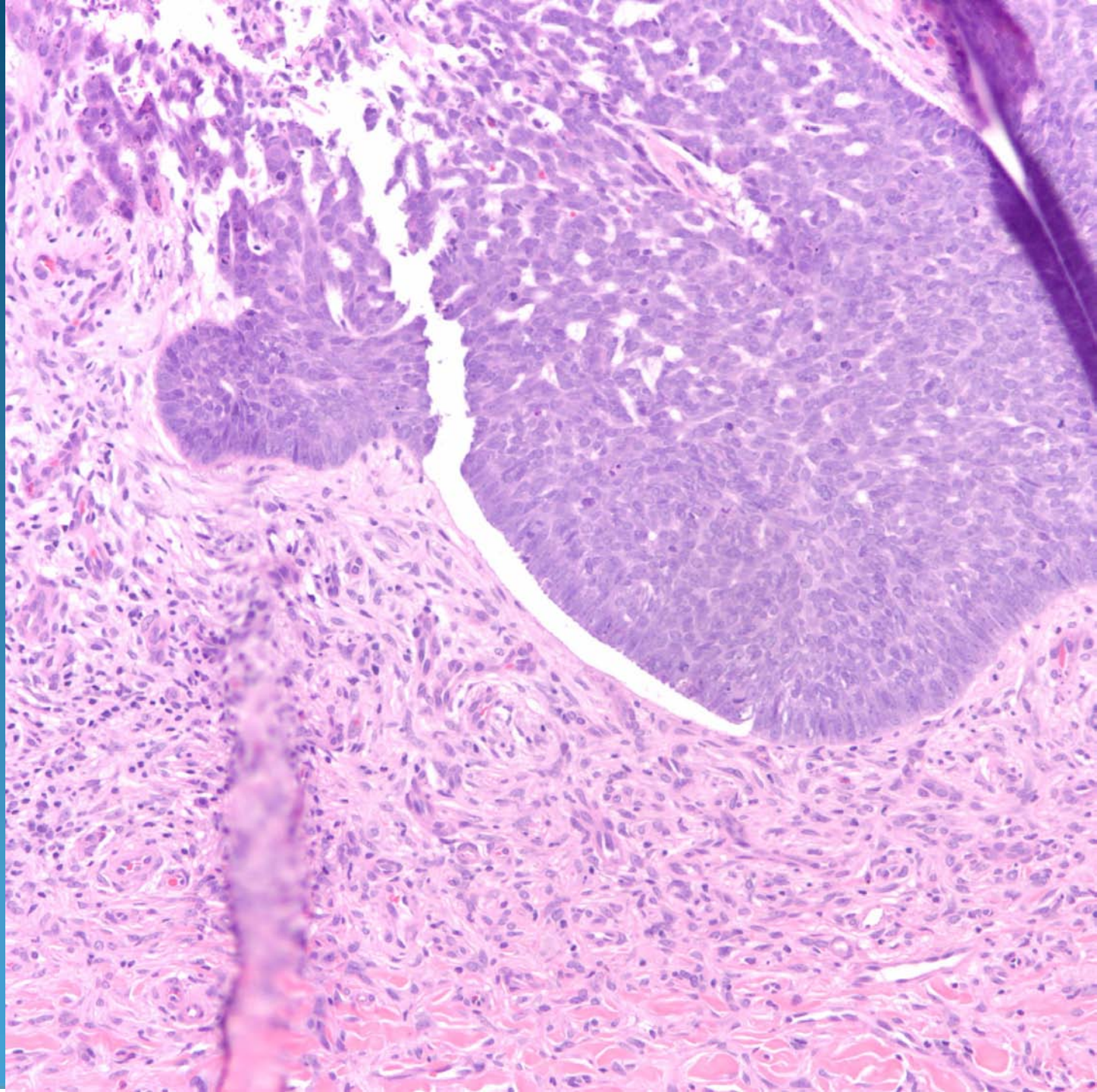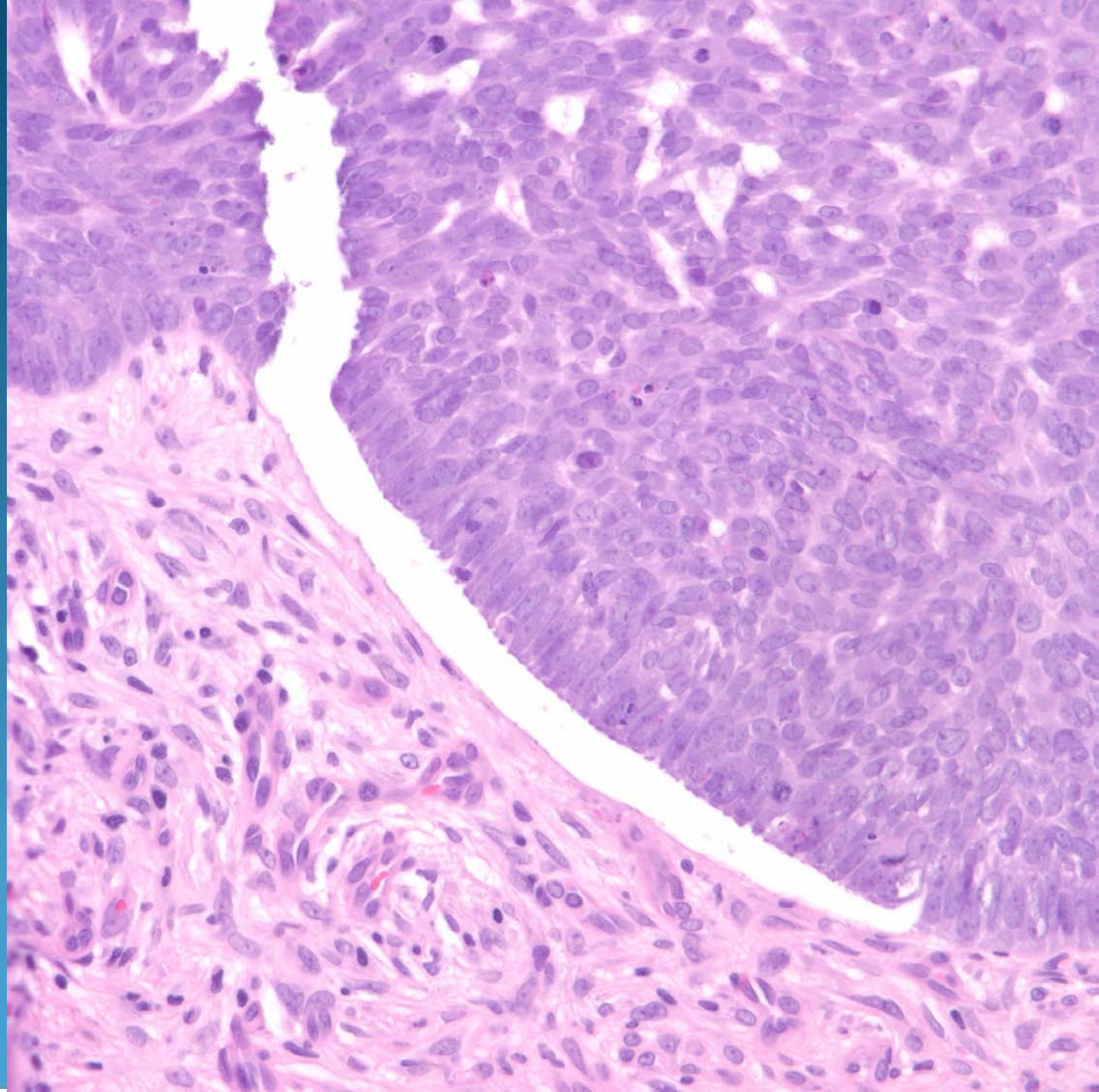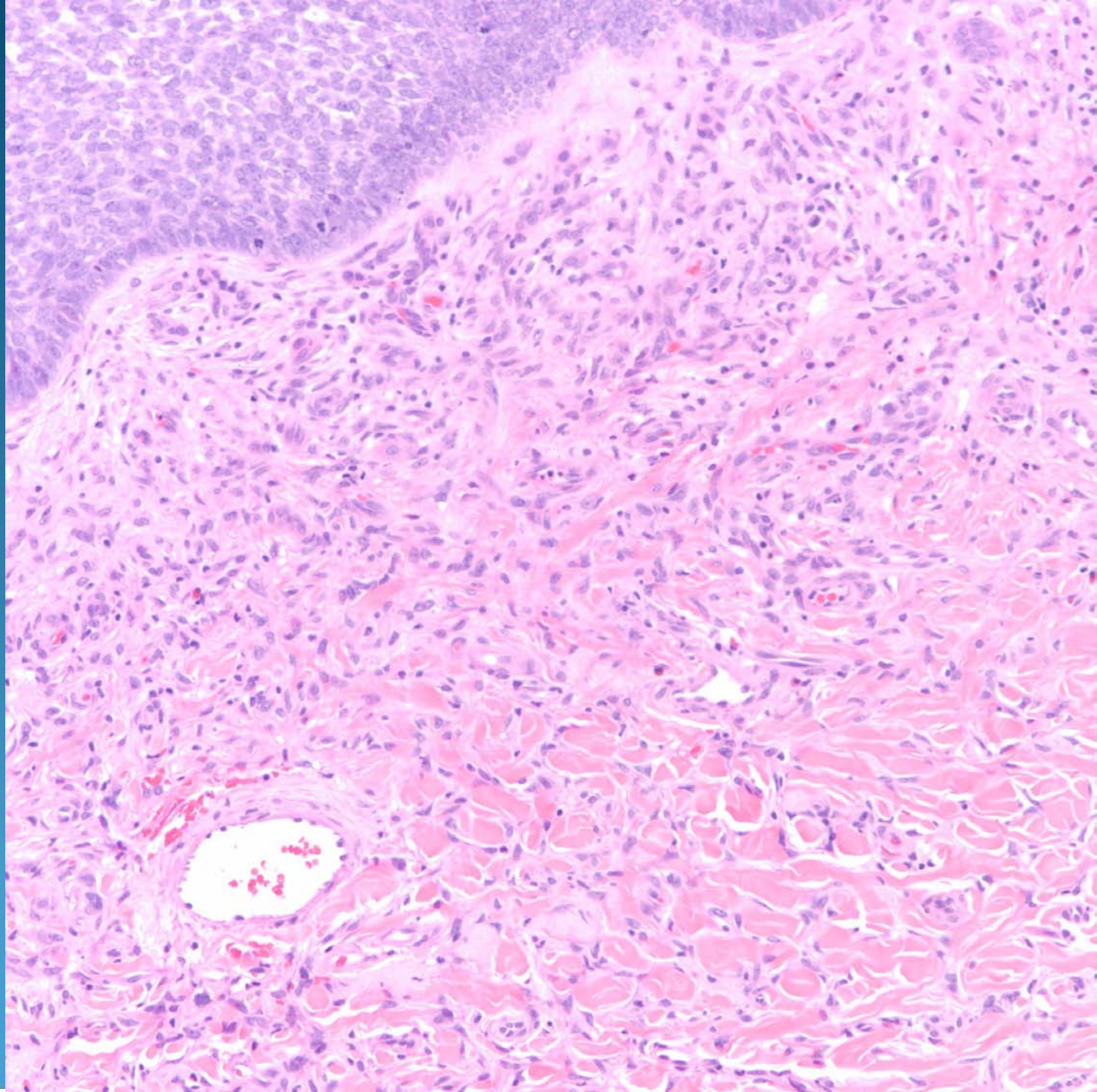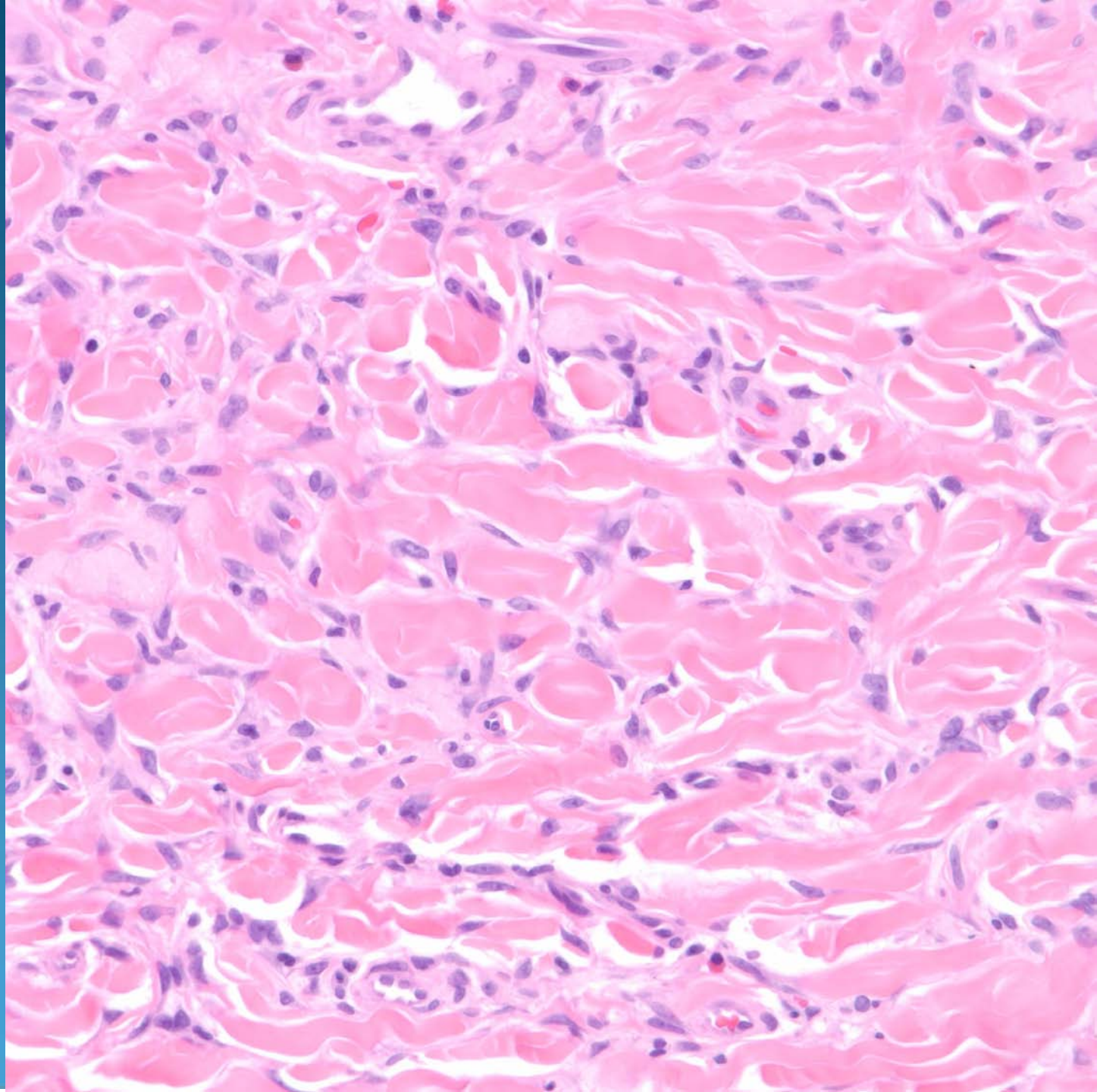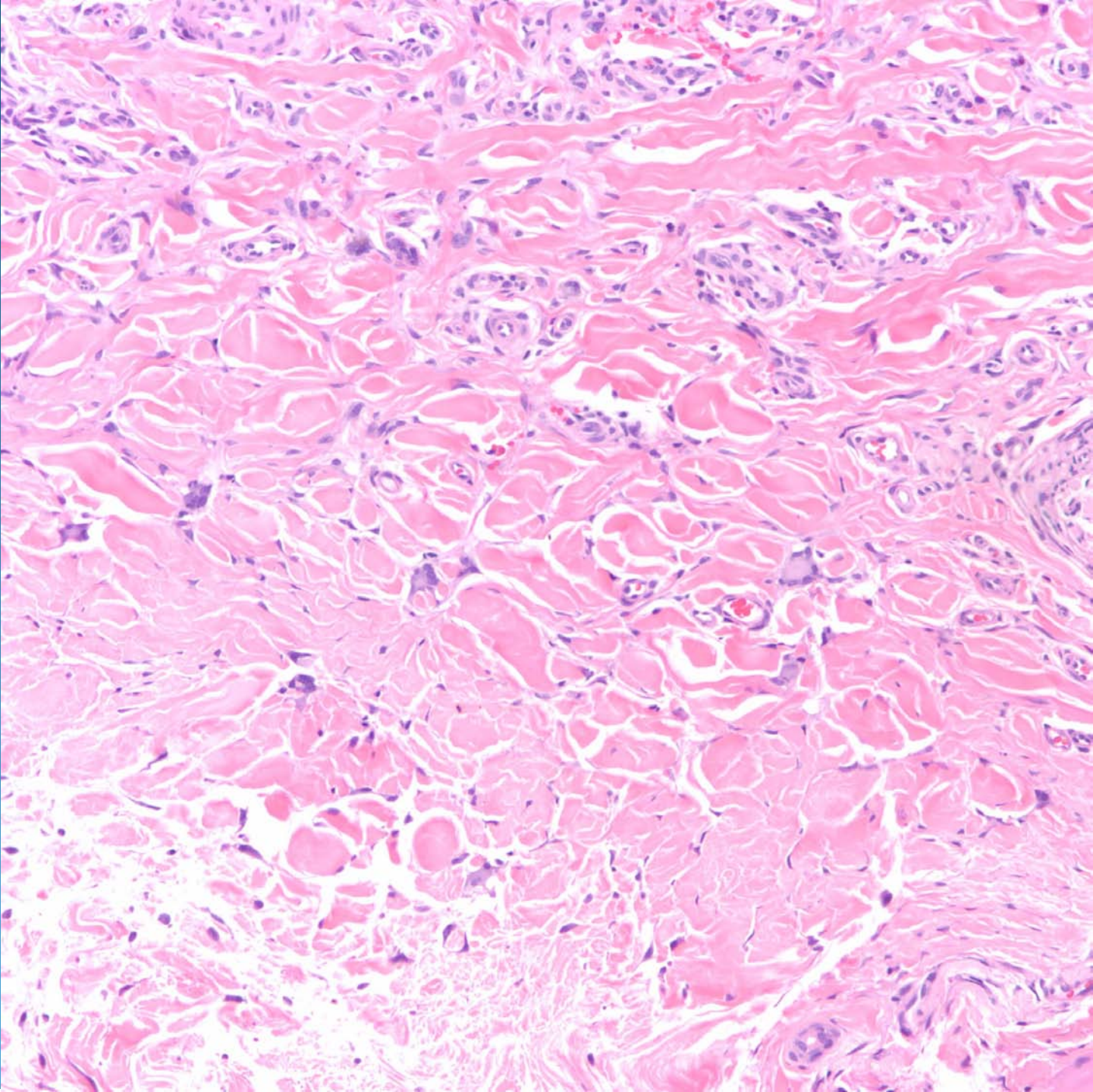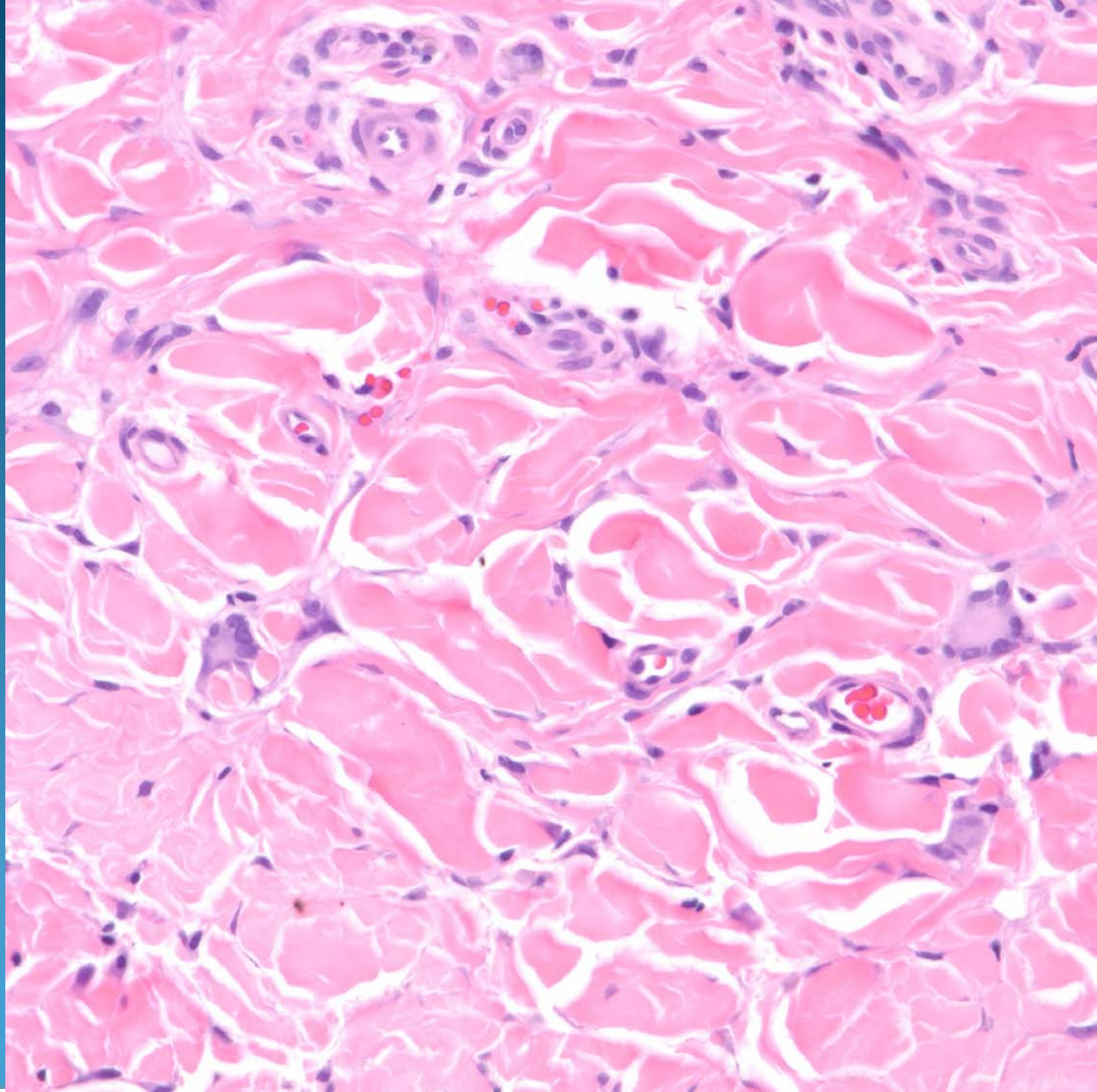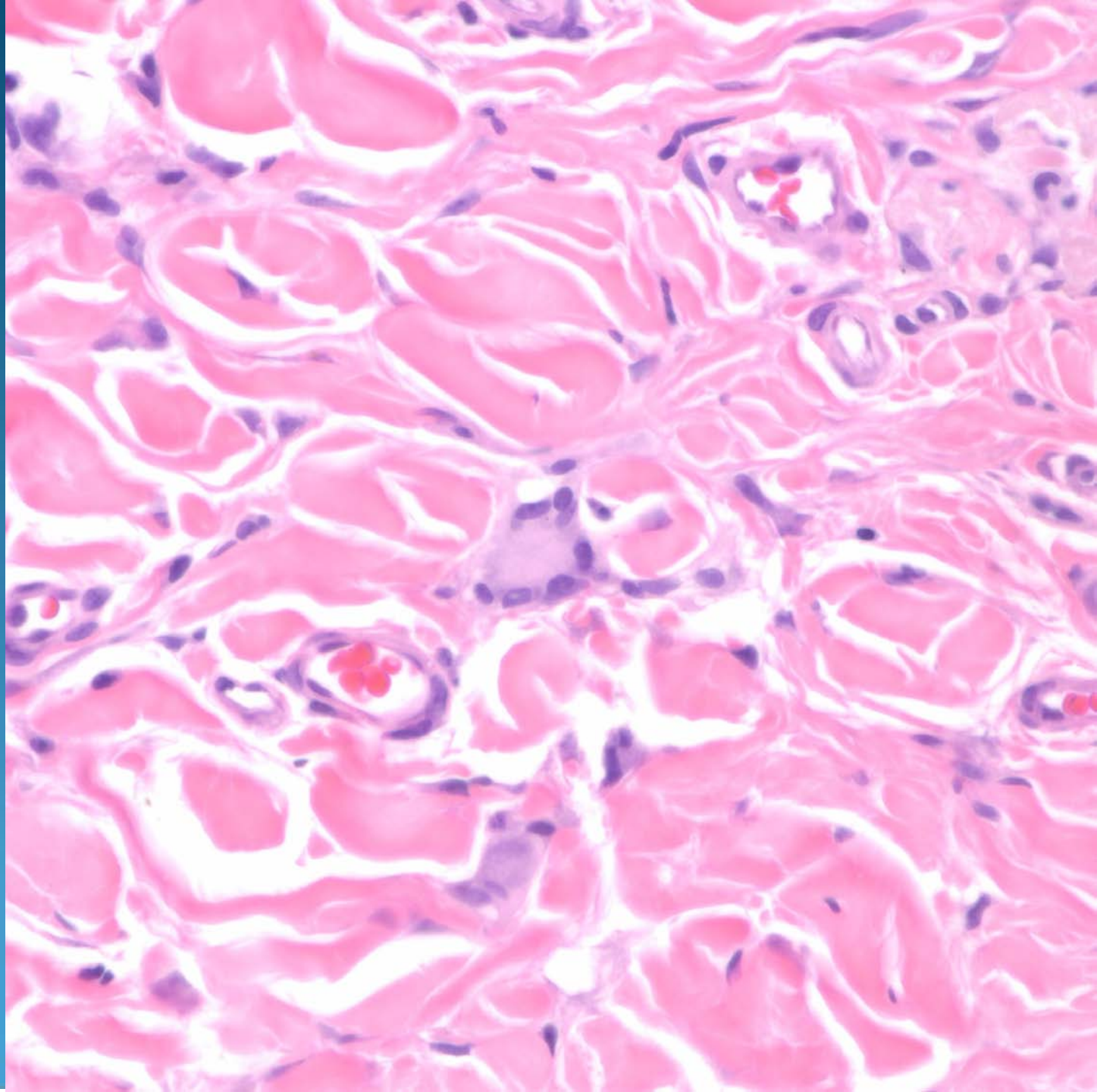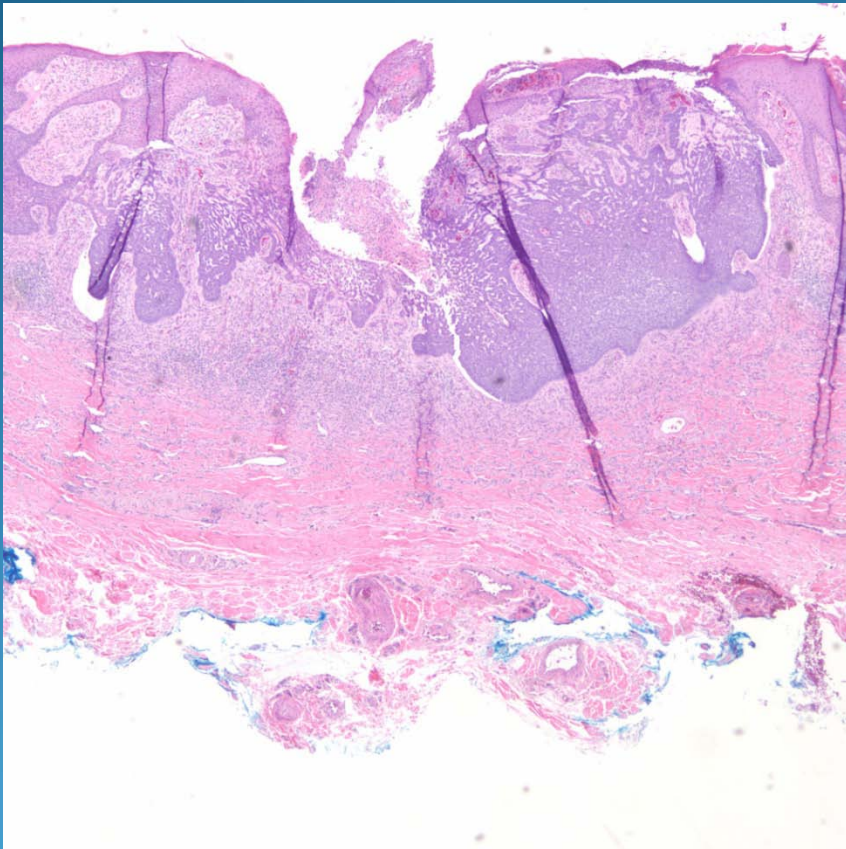


Dermatofibroma arising with true
basal cell carcinoma

Pearls



- Very rare event and must be distinguished from usual basaloid follicular induction that occurs with DF
- Look for marked architectural irregularity of basal cell with minimal to absent follicular differentiation